

Appendix : Dermoscopy

Dermoscopy, also known as dermatoscopy, epiluminescopy and epiluminescent microscopy, is an effective non-invasive diagnostic technique. Dermoscopy improves the accuracy of diagnosis for pigmented skin lesions and has been used increasingly for differential diagnosis of nonpigmented lesions. It allows the in vivo evaluation of colors and microstructures of the epidermis, the dermo-epidermal junction, and the papillary dermis that are not visible to the naked eye. Dermoscopy can be used on lesions to examine the distribution of pigment, the skin surface horny layer, vascular patterns, borders and ulceration. The procedure serves as a valuable aid in diagnosing various skin changes, particularly those of pigmented skin lesions. Dermoscopic patterns are particularly helpful in diagnosing melanomas, moles, freckles, atypical nevi, blue nevi, seborrheic keratoses, basal-cell carcinomas, and hemangiomas.

Dermoscopy involves using dermoscope (dermatoscope), a hand-held imaging device with a built-in illuminating system and a high-quality magnifying lens. A dermoscope is a simple and inexpensive direct skin microscope. Examination takes only short time, and the device is able to record images. Magnification at a power of ten works well for diagnosing pigmented skin lesions. Gel is applied to the skin lesion to reduce reflectivity and to increase the transparency of the stratum corneum.

Examination can be by contact non-polarized light dermoscopy (NPD), polarized light non-contact dermoscopy (PNCD), or contact polarized light dermoscopy (PCD). These give complementary views of skin lesions. Cross-polarized light is capable of showing the subsurface morphology either with or without direct skin contact.

The appendix demonstrates fundamental dermoscopic patterns.





A range of dermoscopy equipment.

a: Delta10 (Heine), b: DermLite (3Gen), c: DermoGenius (Biocam), d: Epilight (Ondeko), e: Derma9500 (Derma Medical), f: Lumio (3Gen).

Reticulation

A grid of thin brown lines on a diffuse, light brown background, covering most of a melanocytic lesion. The color tone may vary with changes in the biologic behavior of the melanocytic lesion.




Frequently seen in...
All categories of melanocytic lesion



Parallel furrow pattern

Bandlike brownish pigmentation on the sulci of skin markings. It is seen in acral skin, palms and soles. It reflects the proliferation of melanocytes in the crista profunda limitans of the epidermis.

Frequently seen in...
Acral lentiginous nevus (benign)



Lattice-like pattern

Linear pigmentation follows and crosses the sulci of skin markings. It is a variant of the parallel furrow pattern.

Frequently seen in...
Acral lentiginous nevus (benign)

Images are available in hardcopy only

Globular pattern

Characterized by the presence of numerous, variously sized, round to oval structures in various shades of brown and grayish-black. They distribute regularly or irregularly within the lesion. This pattern reflects aggregations of pigmented melanocytes, melanophages or even clumps of melanin within the cornified layer, the epidermis, the dermo-epidermal junction or the papillary dermis.

Frequently seen in...
Dysplastic (Clark) nevus, Unna nevus

Images are available in hardcopy only



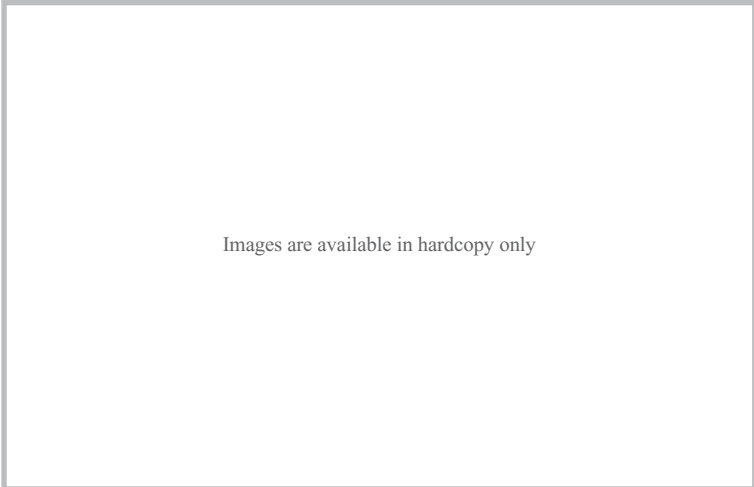
Images are available in hardcopy only

Images are available in hardcopy only

Cobblestone pattern

Closely aggregated globules resemble cobblestones. It is quite similar to the globular pattern.




Frequently seen in...
Unna nevus, Congenital nevus



Parallel-ridge pattern

Bands of brownish pigmentation are seen on ridges of skin markings. It occurs in acral skin. The pattern reflects the proliferation of melanocytes in the crista profunda intermedia of the epidermis.

Frequently seen in...
Malignant melanoma in situ



Multicomponent pattern

Three or more distinct dermoscopic structures present in combination. For instance, the pattern may be made up of pigmented networks, clusters of dots/globules, and areas of diffuse hyper- or hypopigmentation.

Frequently seen in...

Malignant melanoma, Basal cell carcinoma, Seborrheic keratosis

Images are available in hardcopy only

Images are available in hardcopy only

Fibrillar pattern

Fine fibrillar or filamentous pigmentation runs perpendicular to the furrows. It resembles the sweep of a paintbrush.

This pattern is seen in all categories of melanocytic lesion, including malignant melanoma in situ and lentiginous nevus on palms and soles. It reflects melanin granules oriented slanting to skin surface in the horny cell layer.

Frequently seen in...

All melanocytic lesions of acral sites

Images are available in hardcopy only



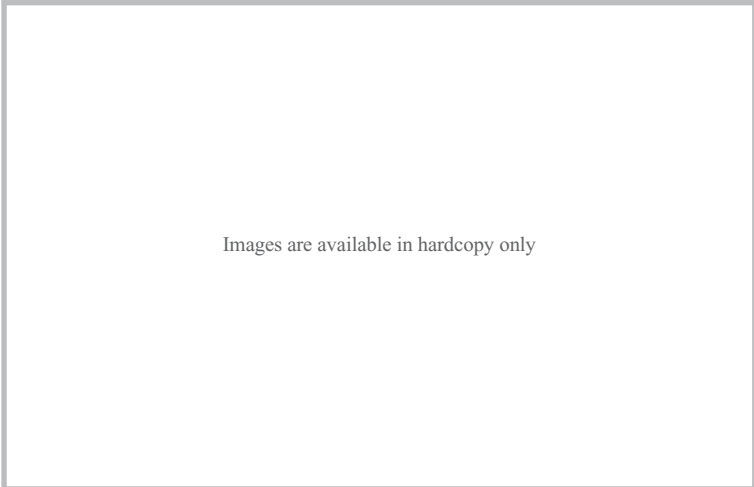
Images are available in hardcopy only

Images are available in hardcopy only

Homogenous blue pigmentation

Sharply demarcated, round to oval, blue or blue-gray pigmented areas without a pigmented network or other distinctive local feature. It reflects the abundance of melanin granules in dermal tumor components.




Frequently seen in...
Blue nevus



Blue-whitish veil

Gray-blue to bluish-white, diffuse pigmentation overlies a whitish film of ground glass appearance. Bluish areas reflect the abundance of melanin granules in dermal tumor components and whitish areas reflect compact orthokeratosis.

Frequently seen in...
Malignant melanoma (invasive),
Spitz nevus



Streaks

Brownish-black linear structures are observed at the periphery of the lesion. They reflect discrete nests of pigmented junctional nevus.

Frequently seen in...
All categories of melanocytic lesion

Images are available in hardcopy only

Images are available in hardcopy only

Images are available in hardcopy only

Atypical pigment network

A black, brown or gray network of irregular meshes is distributed irregularly throughout the lesion, usually ending abruptly at the periphery.

Frequently seen in...
Malignant melanoma

Images are available in hardcopy only

Images are available in hardcopy only

Images are available in hardcopy only

Light-brown fingerprint-like structures

The light brown, finely meshed pigmentation of the peripheral lesion resembles fingerprints. It reflects basal melanosis of the elongated epidermis.

Frequently seen in...
Seborrheic keratosis

Images are available in hardcopy only

Images are available in hardcopy only

Images are available in hardcopy only

Comedo-like openings

These sharply circumscribed structures are yellowish-brown or dark brown, and round to oval. They reflect keratin plugs within dilated follicular openings.

Frequently seen in...
Seborrheic keratosis, Unna nevus

Images are available in hardcopy only

Images are available in hardcopy only

Images are available in hardcopy only

Multiple milia-like cysts

White or yellowish-white, round bodies of various sizes. They reflect intraepidermal keratin cysts.

Frequently seen in...
Seborrheic keratosis

Images are available in hardcopy only

Images are available in hardcopy only

Images are available in hardcopy only

Fissures/ridges (brain-like appearance)

Light brown fissures alternate with dark brown ridges, giving the wrinkled appearance of a brain.

Frequently seen in...
Seborrheic keratosis

Images are available in hardcopy only



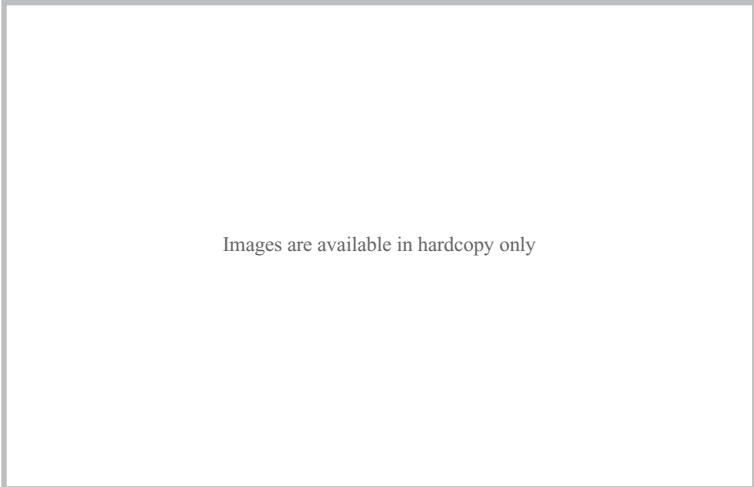
Images are available in hardcopy only

Images are available in hardcopy only

Leaf-like areas (structures)

These are brown to blue-gray, independent, bulbous extensions around the lesion. When big, they sometimes resemble maple leaves. They reflect aggregation of tumor cells that were distributed throughout the epidermis.




Frequently seen in...
Basal cell carcinoma



Arborizing vessels

Telangiectasia with distinct tree-like branching. It reflects dilated vessels of the papillary dermis.

Frequently seen in...
Basal cell carcinoma



Large blue-gray ovoid nests

Well-circumscribed, uniform, pigmented, ovoid or elongated areas larger than blue-gray globules. They reflect large tumor nests with melanin granules.

Frequently seen in...
Basal cell carcinoma

Images are available in hardcopy only

Images are available in hardcopy only

Images are available in hardcopy only

Spoke-wheel areas

Well-circumscribed radial projections. They tend to be more heavily pigmented at the center. When big, they are called leaf-like structures. They reflect tumor nests that are oriented perpendicular to the run of the epidermis.

Frequently seen in...
Basal cell carcinoma

Images are available in hardcopy only



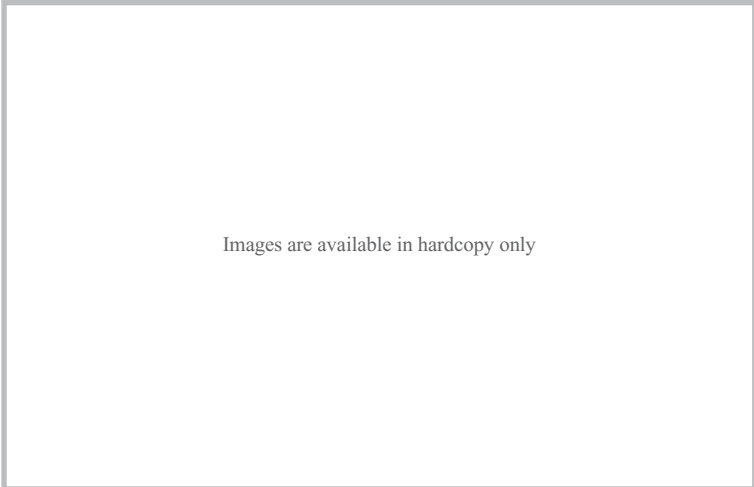
Images are available in hardcopy only

Images are available in hardcopy only

Red-blue lacunae

Sharply demarcated, round to oval areas with reddish, bluish-red or dark-red to black coloration. They reflect dilated vascular spaces and pooling of red blood cells in the upper dermis.

Frequently seen in...
Hemangioma, Angiokeratoma, Subungual and subcorneal hematomas



Hairpin vessels

Long, visible vascular loops that sometimes twist and bend. The diameter remains constant for the entire length of the vessel. They are often seen in the peripheral zone of the lesion.

Frequently seen in...
Malignant melanoma

