

Chapter
9

Erythema, Erythroderma (Exfoliative Dermatitis)

Erythema is caused by telangiectasia or hyperemia in the papillary and reticular dermis. The color disappears with application of pressure. Erythema is a component of a very large number of cutaneous diseases including eczema, urticaria, psoriasis, infectious diseases, blistering diseases and lymphomas. This chapter is devoted to well recognized patterns of erythematous eruptions, with a focus on erythema multiforme, annular erythema and erythroderma (exfoliative dermatitis).

Erythema

A. Erythema multiforme and related diseases

1. Erythema multiforme (EM) ★ ★

Synonym: Erythema exsudativum multiforme (EEM)

Outline

- Multiple circular edematous erythema of 5 mm to 20 mm in diameter occurs multiply and symmetrically on the dorsal hands and the extensor surfaces of the joints.
- EM may occur in patients of all ages, but it occurs predominantly in adolescents and young adults.
- Infection by the herpes simplex virus or mycoplasma pneumoniae is the dominant causative factor of EM, but drug-sensitivities are also an important cause.
- Topical or oral corticosteroids are effective for the treatment of EM. Recurrence may occur.

Classification

Erythema multiforme (EM) is largely classified into localized cutaneous lesions (EM minor) and mucosal lesions with systemic involvement (EM major). EM major is thought to be the same as Stevens-Johnson syndrome. Both EM minor and EM major are transitory. These prototypes are well defined, but their distinction may be difficult in practice because of their overlapping features.

Clinical features, Epidemiology

Eruptions occur symmetrically on the extensor aspects of the joints (e.g., the dorsal hands, elbows, knees) as erythematous papules or edematous erythema, and they spread centrifugally in about 48 hours to form sharply circumscribed, round or irregularly shaped erythema (Figs. 9.1-1 and 9.1-2). The center of the erythema is concave, presenting either as a target lesion or iris formation, also called exudative erythema. The affected area simultaneously shows new and old lesions that may fuse into





Fig. 9.1-1 Erythema multiforme (EM). Well-demarcated edematous exudative erythema disseminates on the dorsal hand (a) and elbow (b). The size is up to 2 cm. Note the central concavities.



Clinical images are available in hardcopy only.

Fig. 9.1-2 Erythema multiforme (EM).
The central concavities give a characteristic iris-like appearance.

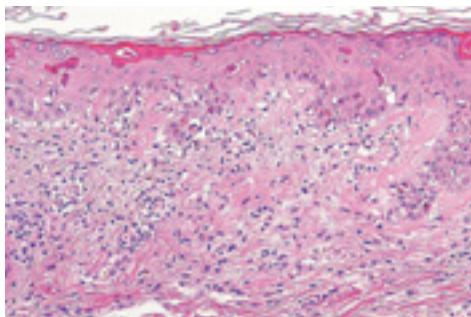


Fig. 9.2 Histopathology of erythema multiforme (EM).
Necrosis of epidermal cells (staining strongly red by eosin), vacuolar degeneration of the basal layer, inflammatory cell infiltration and edema in the upper dermis are noted.

map-like patterns. EM may be accompanied by blistering (bullous EM) and erosions of the oral mucosa.

EM frequently occurs in the young and middle-aged, and it tends to appear during the spring and summer. Infectious symptoms including high fever and pharyngodynia may precede the onset. In cases caused by herpes simplex infection, EM tends to occur 1 to 3 weeks after the onset of the herpes simplex symptoms (post-herpetic EM).

Pathogenesis

As shown in **Table 9.1**, EM is caused by various factors, such as viral or bacterial infections (by herpes simplex or *Mycoplasma pneumoniae*), and drugs and malignant tumors. It is estimated that EM is a cell-mediated immuno reaction leading to the destruction of keratinocytes expressing various antigens. However, the underlying pathomechanism is not known.

Pathology

In the early stages of epidermal EM, there is lymphocytic infiltration into the dermo-epidermal junction and vacuolar degeneration of basal cells. As the disease progresses, lymphocytes (CD8⁺T cells) infiltrate into the epidermis, and necrosis of epidermal cells and subepidermal blistering are found (**Fig. 9.2** and

Table 9.1 Conditions associated with erythema multiforme.

| Cause | Details |
|---------------------------------------|---|
| Infections | Virus (e.g., human herpes simplex virus), bacteria (<i>Streptococcus</i> , <i>Mycoplasma</i> , <i>Mycobacterium</i>), tinea, <i>Chlamydia</i> , <i>Rickettsia</i> |
| Drug reactions | Antibiotics, NSAIDs, anticonvulsants, antineoplastic agents, etc. See Chapter 10. |
| Collagen diseases, Allergic disorders | Insect bite, disease (especially systemic lupus erythematosus (SLE)), sarcoidosis, Crohn's disease |
| Other | Physical stimulation (e.g., cold), hematopoietic malignant disorders, pregnancy, etc. |

Table 9.2 Histopathological classification of erythema multiforme.

| Classification | Main histopathological findings |
|----------------|---|
| Epidermal | In the early stage, lymphocytic infiltration and ballooning degeneration in the dermo-epidermal junction. As the disease progresses, infiltration of CD8 ⁺ lymphocytes into the epidermis, resulting in keratinocyte necrosis and subepidermal blistering. Decrease of epidermal Langerhans cells and overexpression of ICAM-1 on keratinocytes. |
| Dermal | Perivascular monocyctic infiltration in the upper dermis; edema in the dermal papilla. It is now said that erythema multiforme is always accompanied by at least some change in the epidermis. |
| Mixed | Epidermal changes (vacuolar degeneration of the basal layer, satellite cell necrosis); dermal changes (perivascular lymphocytic infiltration). |

Table 9.2).

Laboratory findings

Because of inflammation, CRP may be positive and the erythrocyte sedimentation rate is elevated. The herpes simplex virus antibody titer, *Mycoplasma* antibody titer and antistreptolysin O (ASO) titer may be elevated in some cases. In cases involving bacterial infection, there is an increase in neutrophils.

Diagnosis, Differential diagnosis

EM is relatively easy to diagnose by its characteristic clinical features and by the distribution of the eruptions. History of previous diseases, such as infectious diseases, supports the diagnosis. Refer to **Table 9.3** for differential diagnosis.

Treatment, Prognosis

Identifying the pathogenesis is important not only for treatment but also for prevention of recurrence. The underlying infectious disease should be treated. Topical steroids, oral antihistamines, NSAIDs and potassium iodides may also be used. Severe cases need the application of systemic corticosteroids. EM regresses spontaneously within 2 to 4 weeks. When caused by herpes simplex infection, acyclovir administration may be effective; however, EM tends to recur.

2. Stevens-Johnson syndrome (SJS) ★★

Synonyms: Mucocutaneous ocular syndrome, EM major

Outline

- SJS is a severe acute mucocutaneous reaction with systemic symptoms such as fever and arthralgia.
- It may develop into toxic epidermal necrolysis (TEN).
- When the symptoms are severe, systemic corticosteroids is administered. Steroid pulse therapy and systemic management may also be adopted.

Classification

Stevens-Johnson syndrome (SJS) is EM major with oculomucous lesion and systemic symptoms including liver and renal dysfunction. Nevertheless, well-defined findings on the differences between EM major and SJS have not been obtained. Drugs are clearly the leading causative factor of SJS. The disease occurs 1 to 6 cases per million population per year. It is sometimes difficult to draw an absolutely clear distinction between SJS and toxic epidermal necrolysis (TEN) (Chapter 10).

Clinical features

EM occurs suddenly, with systemic symptoms such as high fever, general fatigue, arthralgia, myalgic pain, chest pain and gastrointestinal distress (**Figs. 9.3-1** and **9.3-2**). Intense edematous

Table 9.3 Erythema multiforme: differential diagnosis.

| Disorder | Difference from erythema multiforme |
|--------------------|---|
| Urticaria | Itching is more severe. Each lesion usually disappears within 24 hours. Dermographism rubrum occurs. |
| SLE | Systemic symptoms occur (renal, arthritic, etc.). Laboratory findings of antinuclear antibodies, etc. Erythema multiforme sometimes occurs in association with SLE. |
| Bullous pemphigoid | Direct/indirect immunofluorescence reveals antibodies against basement membrane. |





Fig. 9.3-1 Stevens-Johnson syndrome (SJS).
 a, b: Erythema multiforme rapidly spreads on the entire body. Some lesions overlap to form large plaques on the back. A bull's-eye pattern, characteristic of erythema multiforme, is seen at the border of a plaque.

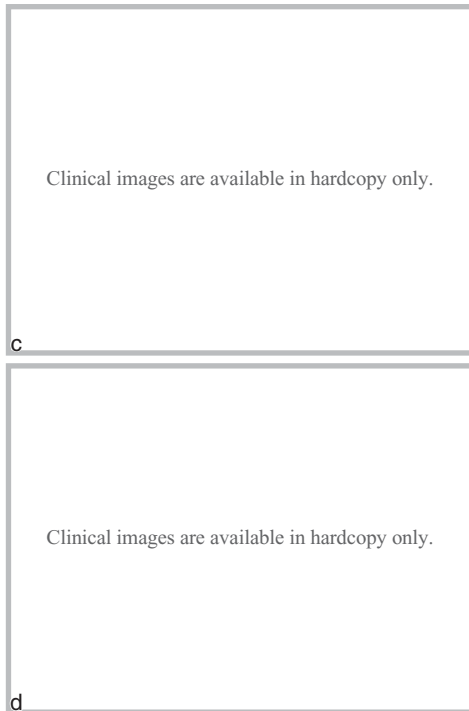


Fig. 9.3-2 Stevens-Johnson syndrome (SJS).
c: Large plaques. d: Erosions and ulcers are seen on the oral mucosa and tongue, with severe pain.

Differentiation between SJS and TEN



Both Stevens-Johnson syndrome (SJS) and toxic epidermal necrolysis (TEN) produce necrotic lesions over the skin and mucous membranes on the whole body. When the area of epidermolysis is 10% or less, the disease is called SJS; when it is 30% or more, the disease is called TEN.

EM major, accompanied by blistering and bleeding, develops and tends to be severe. The extensor surface of the extremities and the entire body surface including the face and trunk are affected. Mucosal sites are involved and may be severe. Erythema, hemorrhagic bullae, and erosions accompanied by pus and bloody crusts occur in the eyes, oral cavity, nose, perineal regions, and genital mucosa. Patients sometimes cannot eat or excrete because of severe pain. Systemic treatment is essential for cases with involvement of hepatopathy and renal dysfunction. Conjunctival inflammation, adhesion, corneal opacity and ulceration occur in the eyes. When it heals, SJS may leave serious aftereffects, such as loss of eyesight. Dense fibrous adhesion (symblepharon) between the conjunctival linings is also seen. Ocular involvement in SJS requires early consultation with an ophthalmologist.

Pathology

Refer to the section on erythema multiforme. Necrotic degeneration is found mostly in the epidermis. Vacuolar degeneration of the basal membranes and dermal edema are also present.

Diagnosis, Differential diagnosis

SJS is characterized by severe lesions in the mucocutaneous junction, erythema over the entire body surface, blisters, erosions and systemic symptoms, and histopathologically by epidermal necrotic degeneration. A detailed medical history is needed to identify the cause. Antibody titers of HSV, *Mycoplasma*, pharynx culture and chest X-ray are performed. Sudden enlargement on the entire body suggests progression to TEN.

Treatment

Early diagnosis and treatment are important for improving the prognosis. Systemic steroid administration (orally or by pulse therapy) is especially important in the early stages. The causative drug should be discontinued immediately. The skin and mucous membranes should be protected by ointment application.

Prognosis

Unless the patient is treated appropriately, SJS may develop into TEN, and the patient may die of pneumonia or renal dysfunction. In severe cases, it leaves corneal opacity and conjunctival adhesion.

3. Sweet's disease ★ ★

Synonyms: Acute febrile neutrophilic dermatosis, Neutrophilic dermatosis

Outline

- In Sweet's disease, painful erythema with elevated borders occurs on the face and joints.
- Fever, neutrophilia and arthralgia appear simultaneously.
- Histopathologic features are edema of dermal papillae and dense infiltration of leukocytes in the dermis.
- It is associated with hematologic malignancies (commonly acute myelogenous leukemia and myelodysplastic syndrome (MDS)).
- The treatments of systemic corticosteroids, colchicines and potassium iodides are effective.

Clinical features

Sweet's disease occurs most frequently on the face, neck, forearms and dorsal hands of middle-aged women. Several days to 4 weeks after upper respiratory tract infection, multiple painful and sharply circumscribed dark reddish edematous erythema 10 mm to 25 mm in diameter occur suddenly, accompanied by high fever (**Fig. 9.4**). The surface of the eruptions is rough and granular, and the eruptions are surrounded by vesicles and pustules. Central clearing may lead to annular or accurate patterns. When Sweet's disease occurs on the lower thighs, it resembles erythema nodosum. Differentiation from Behçet's disease may be necessary if oral aphtha is found.

Pathogenesis

Hypersensitive reaction occurs against *Streptococcus* and other pathogens in certain circumstances, such as the presence of a hematopoietic malignant tumor, solid tumors, or various autoimmune disorders. Sweet's disease is caused by abnormally activated neutrophils; the details of the pathomechanism are not known.

Complications

Sweet's disease often accompanies the diseases listed in **Table 9.4**. 10% to 15% of the Sweet's disease is reported to be associated with hematologic malignancies.

Pathology

The main and most striking feature is a massive infiltration of neutrophils in the dermis and dermal edema (**Fig. 9.5**). Changes on the epidermis and vasculitis (fibrinoid necrosis) are not observed. In the chronic stage, lymphocytic perivascular infiltration occurs instead of neutrophilic infiltration.

Laboratory findings, Diagnosis

Peripheral leukocytosis with neutrophilia is the characteristic

Clinical images are available in hardcopy only.

Clinical images are available in hardcopy only.

Fig. 9.4 Sweet's disease.

Table 9.4 Disorders associated with Sweet's disease.

| Disorder type | Details |
|---------------|--|
| Hematological | Myelodysplastic syndrome (MDS), leukemia, myelofibrosis, etc. |
| Autoimmune | Sjögren syndrome, rheumatoid arthritis, subacute cutaneous lupus erythematosus, ulcerative colitis, etc. |
| Other | Other malignancy, pyoderma gangrenosum, etc. |

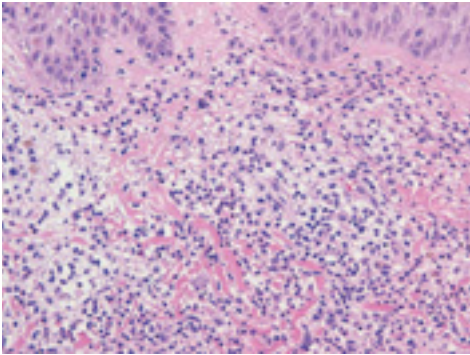


Fig. 9.5 Histopathology of Sweet's disease.
Dense neutrophilic infiltration on the entire dermis without apparent vasculitis.

laboratory finding. An elevated erythrocyte sedimentation rate and high CRP levels are also present. Sweet's disease is often associated with an underlying disease. It is necessary to determine whether the primary disease is lymphoma (myelodysplastic syndrome, leukemia), malignant internal-organ tumor or autoimmune disease.

Treatment

Oral administration of corticosteroids, potassium iodides, NSAID and colchicines are the main treatments. Antibiotics are ineffective.

Prognosis

Without treatment, the eruption may persist for weeks or even months. Patients with cancer may see frequent recurrences.

4. Palmar erythema ★ ★

Clinical features

Palmar erythema is observed in several conditions.

Pathogenesis

Palmar erythema is a vascular acrosyndrome with multiple etiologies. Best known in pregnancy, liver diseases and collagen diseases (e.g., erythematosus, dermatomyositis, rheumatic arthritis), it can occur in a variety of other systemic disturbances. Palmar erythema may be related to elevated serum estrogens and related 17-cetosteroid hormones. In rare cases it occurs hereditarily in otherwise healthy people.

Refer to Chapter 18 for erythema nodosum and erythema induratum.

B. Annular erythema ★ ★

Annular erythema is a general term for diseases in which small erythema appear and then spread centrifugally. It begins with small erythema that enlarge centrifugally while resolving in the center, resulting in a ring shape. It may involve an underlying disease, such as an infectious disease, malignant tumor, drug eruption or collagen disease. Annular erythema is classified according to the underlying disease and the clinical features (**Table 9.5**). Refer to Chapter 12 for Sjögren syndrome and the annular erythema associated with LE.